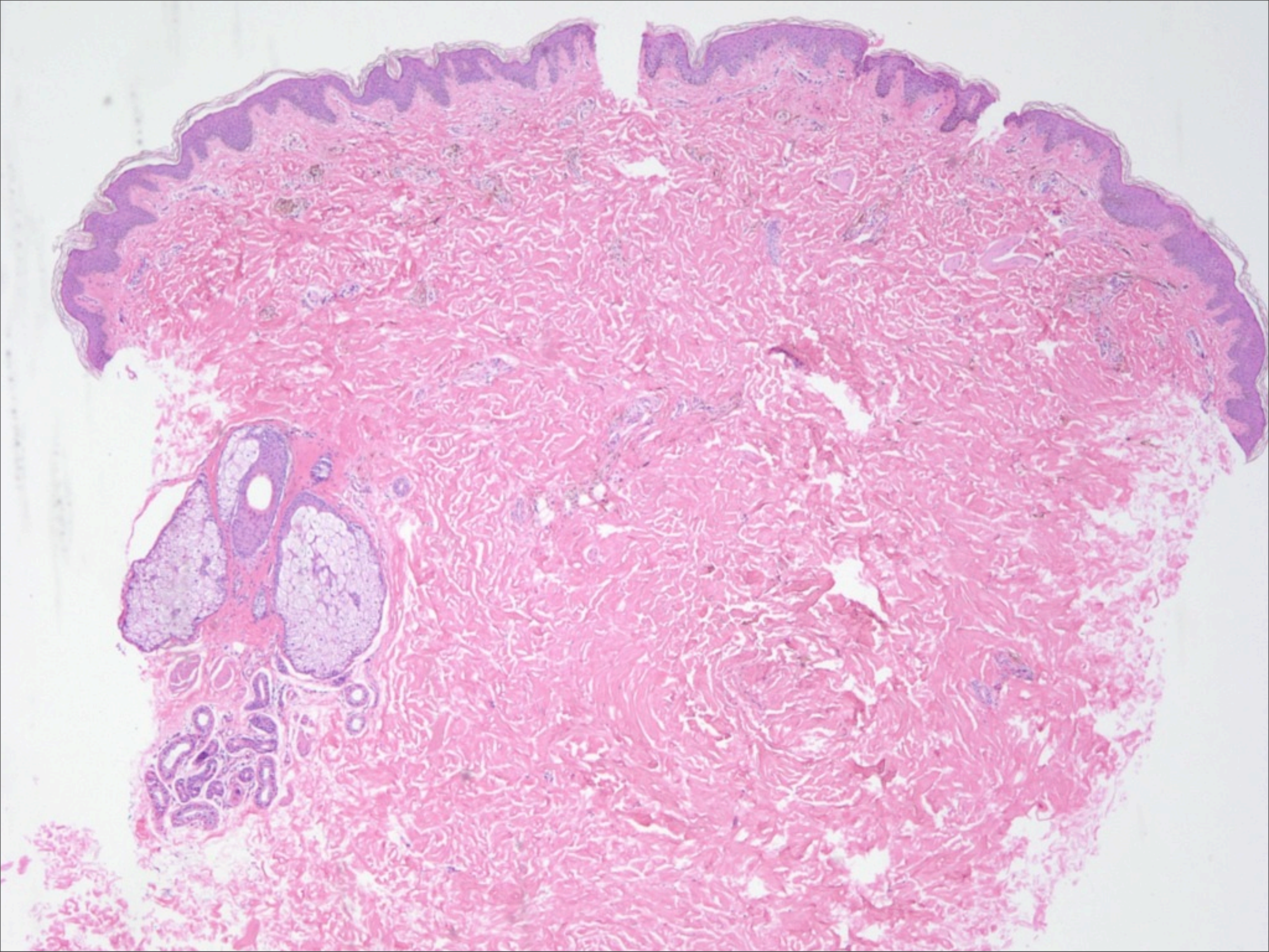
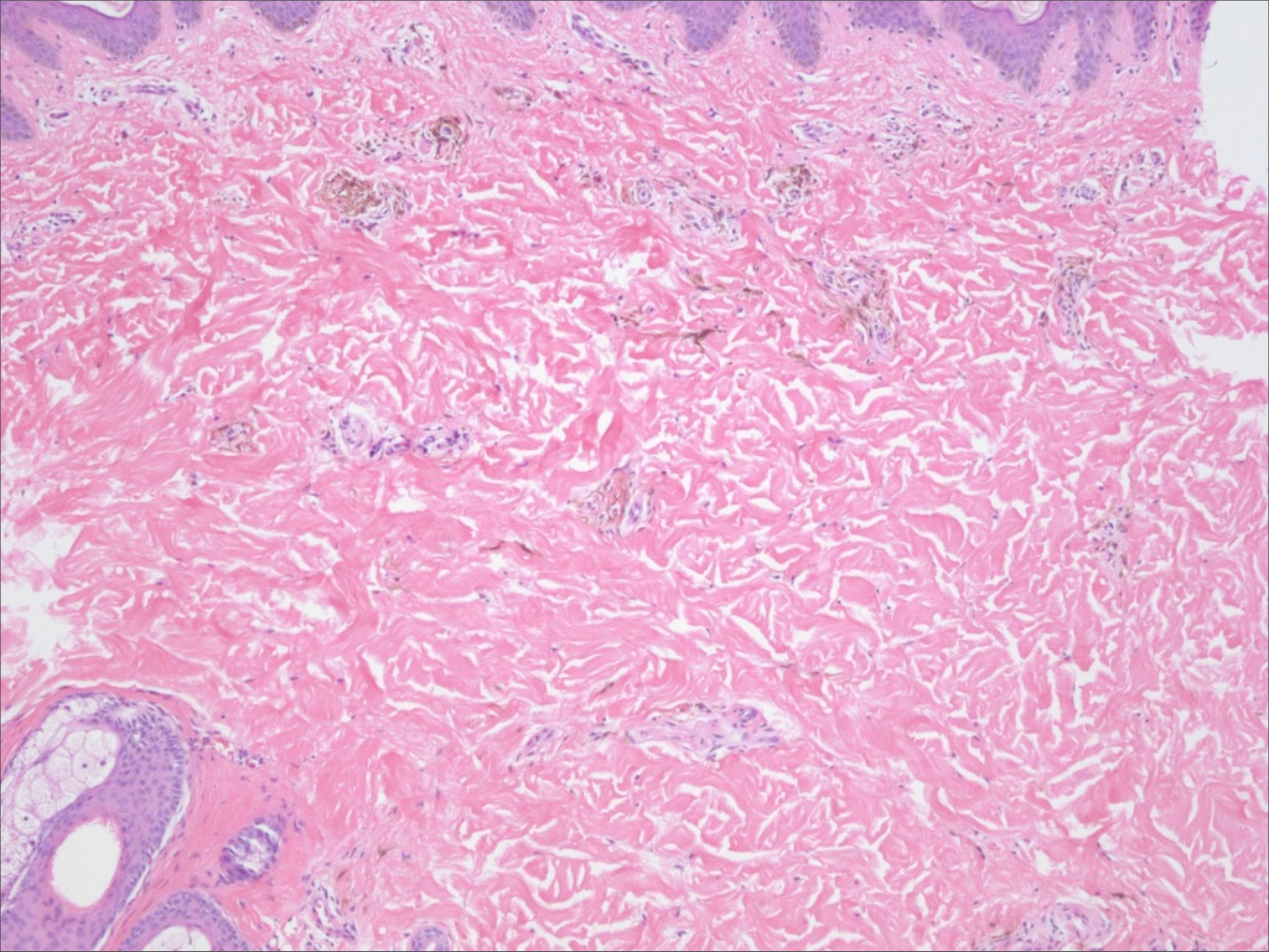
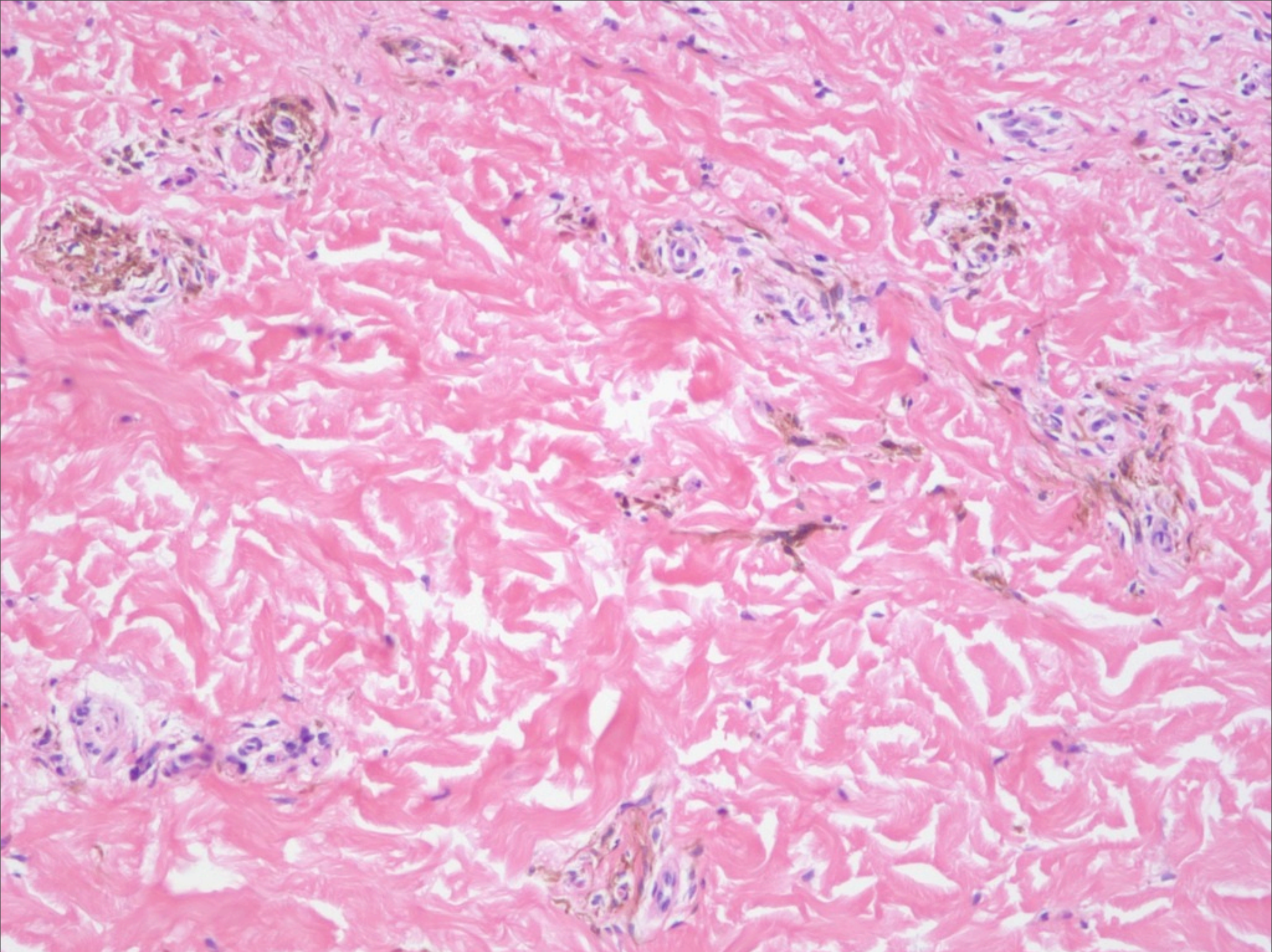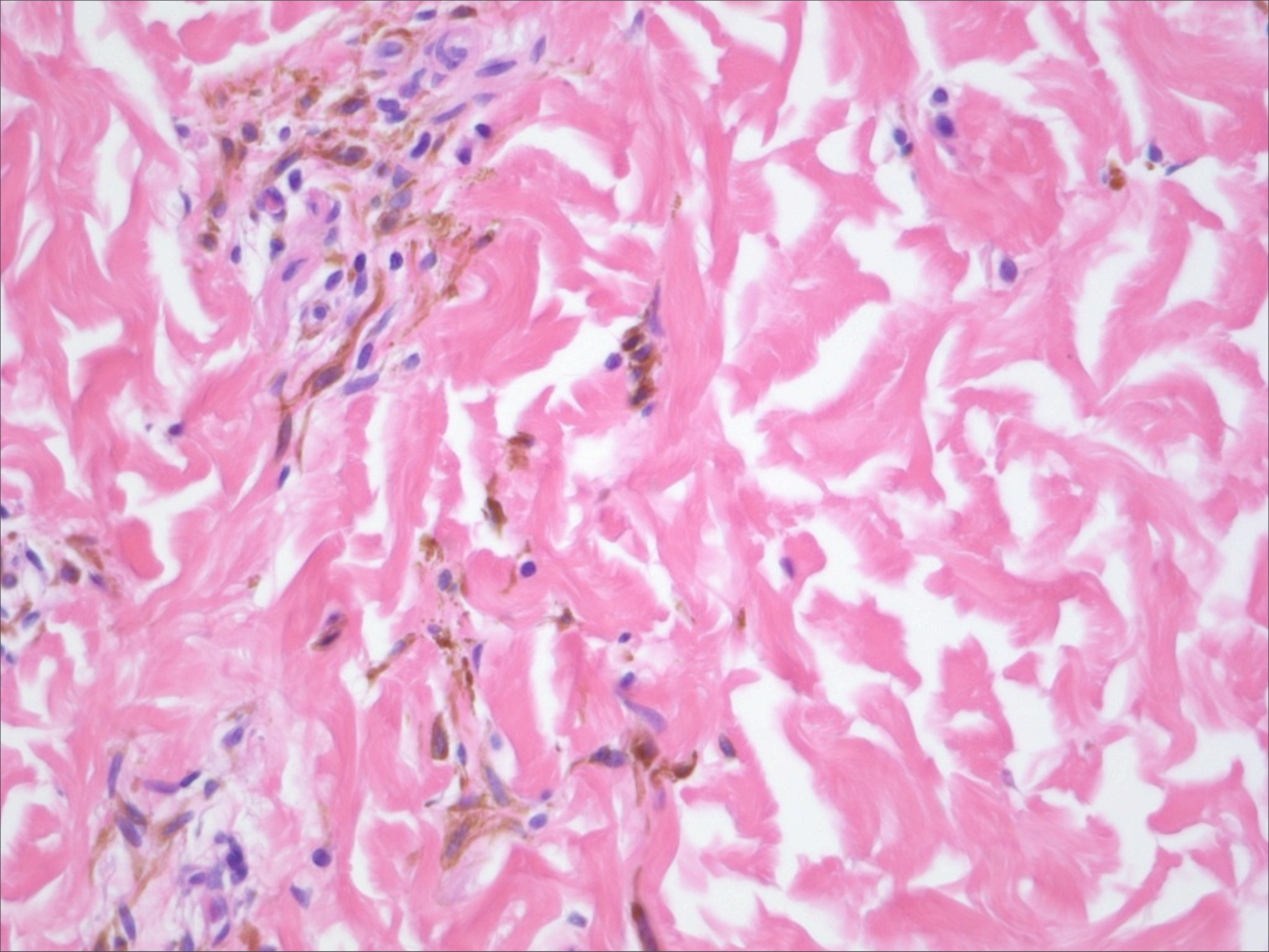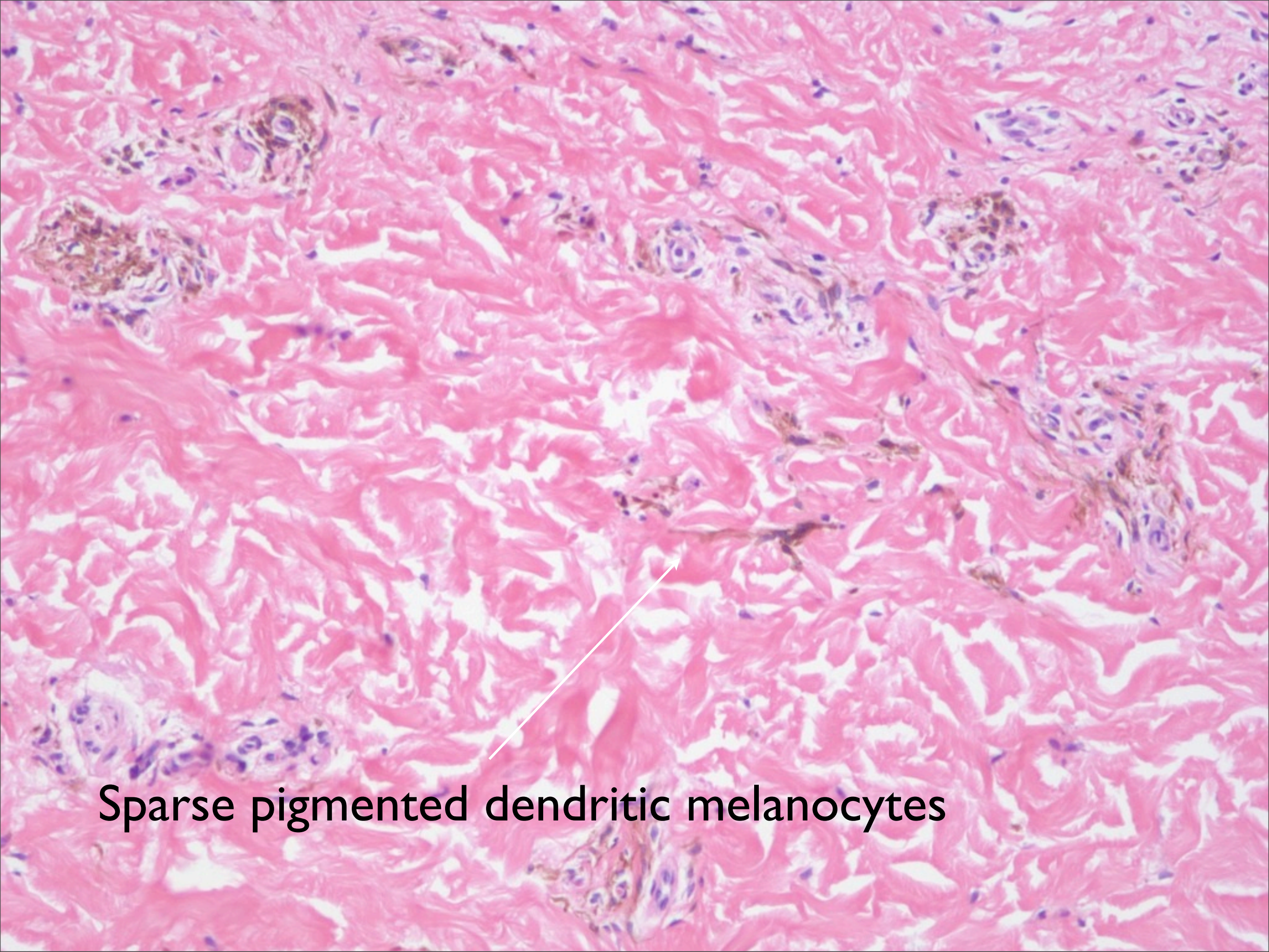


# Mongolian Spot

# Notes

- Histologically contains dendritic melanocytes
- DDX: Blue nevus, Nevus of Ito, Nevus of Ota
- Distinguish by clinical presentation





Sparse pigmented dendritic melanocytes